

See discussions, stats, and author profiles for this publication at: <https://www.researchgate.net/publication/280627454>

# An Overview of Musculoskeletal Injuries for Emergency Physicians

Article in *Open Journal of Emergency Medicine* · September 2015

DOI: 10.17140/EMOJ-1-113

CITATIONS

0

READS

1,049

16 authors, including:



**Bruno Monteiro Tavares Pereira**  
University of Campinas

96 PUBLICATIONS 615 CITATIONS

[SEE PROFILE](#)



**Luis G Fernandez**  
CHRISTUS MOTHER FRANCES HOSPITAL

37 PUBLICATIONS 644 CITATIONS

[SEE PROFILE](#)



**Juan Pablo Herrera-Escobar**  
Brigham and Women's Hospital

36 PUBLICATIONS 56 CITATIONS

[SEE PROFILE](#)



**Carlos Alberto Ordoñez**  
Fundación Valle del Lili, Universidad del Valle (Colombia)

121 PUBLICATIONS 1,399 CITATIONS

[SEE PROFILE](#)

Some of the authors of this publication are also working on these related projects:



Imtanan Raza [View project](#)



intraabdominal sepsis [View project](#)

## Review

**\*Corresponding author:****Bruno M. Pereira**, MD, MSc, PhD, FACSAssistant Professor  
Department of Surgery  
Division of Trauma  
University of Campinas  
Rua Alexander Fleming, 181  
São Paulo, Brazil

Tel. (55-19) 3521-9450

E-mail: [drbrunompereira@gmail.com](mailto:drbrunompereira@gmail.com)

Volume 1 : Issue 3

Article Ref. #: 1000EMOJ1113

**Article History:**Received: June 28<sup>th</sup>, 2015Accepted: July 31<sup>st</sup>, 2015Published: August 3<sup>rd</sup>, 2015**Citation:**Pereira BM, Fernandez LG, Garcia GD, et al. An overview of musculoskeletal injuries for emergency physicians. *Emerg Med Open J*. 2015; 1(3): 77-88.**Copyright:**

© 2015 Pereira BM. This is an open access article distributed under the Creative Commons Attribution License, which permits unrestricted use, distribution, and reproduction in any medium, provided the original work is properly cited.

# An Overview of Musculoskeletal Injuries for Emergency Physicians

**Bruno M. Pereira<sup>1\*</sup>, Luis G. Fernandez<sup>2</sup>, George D. Garcia<sup>3</sup>, Supparek Prichayudt<sup>4</sup>, William Sánchez<sup>5</sup>, Marcela dos S. Martins<sup>6</sup>, Juan P. Herrera-Escobar<sup>7</sup>, Taichiro Tsunoyama<sup>8</sup>, Carlos Ordoñez<sup>9</sup> and Gustavo Pereira Fraga<sup>10</sup>**<sup>1</sup>Assistant Professor, Department of Surgery, Division of Trauma, University of Campinas, São Paulo, Brazil<sup>2</sup>Brigadier General, Commanding General, Texas Medical Brigade, US Army, Austin, TX, USA<sup>3</sup>Lt Col. US Army, Division of Trauma & Surgical Critical Care, University of Miami, USA<sup>4</sup>Department of Surgery, Chulalongkorn University, Bangkok, Thailand<sup>5</sup>Chief-Department of Surgery, Central Military Hospital (HOMIC), University Nueva Granada, Bogotá, Colombia, USA<sup>6</sup>Faculty of Medical Sciences, University of Campinas, São Paulo, Brazil<sup>7</sup>Clinical Research Center, Fundación Valle del Lili, Cali, Colombia, USA<sup>8</sup>University of Teikyo, Trauma and Resuscitation center, Tokyo, Japan<sup>9</sup>Hospital Universitario del Valle, Fundación Valle del Lili, Chief-Department of Surgery, Universidad del Valle, Cali, Colombia, USA<sup>10</sup>Chief, Division of Trauma, University of Campinas, São Paulo, Brazil**ABSTRACT**

Musculoskeletal trauma includes injuries affecting the pelvis, upper and lower limbs. These injuries occur in a large number of multiply-injured patients and, as such, are often underestimated, incorrectly treated, and occasionally undiagnosed. This leads to increased morbidity, mortality, and permanent dysfunction of the affected limb. Herein, the authors discuss the most common injuries and those that cause life threat or limb loss, intending to schematize the first aid to extremity trauma in the Emergency Room (ER). Although, the definitive treatment of fractures and joint injuries is managed by the orthopedist, the first steps properly taken by the emergency physician are essential for an accurate prognosis and appropriate triage.

**KEYWORDS:** Physicians; Trauma; Injuries; Fractures; Patient**ABBREVIATIONS:** ER: Emergency Room; TBI: Traumatic Brain Injury**INTRODUCTION**

Trauma is the leading causes of death in people under 44 years of age.<sup>1-2</sup> Musculoskeletal trauma occurs in 85% of those patients experiencing such trauma.<sup>1-2</sup> In the USA, 80,000 people per year sustain traumatic injuries and suffer permanent disability.<sup>1-2</sup> It is estimated that over 36 million emergency room visits are made each year for sustained musculoskeletal trauma, equating to over 442,850 deaths and 2 million hospital admissions.<sup>3</sup> The mechanisms of injury can vary from automotive collisions (head-on crush injuries, lateral impact, ejection, auto vs. pedestrian) along with injuries attributed to rapid vertical deceleration (falls) and gunshot wounds (Table 1). These can be a source of confusion and mismanagement when encountered by first responders. Open fracture classification, attributed to Gustilo & Anderson, (Table 2) is an essential tool for fracture assessment. Classification is based on wound length, soft tissue injury, contamination, and fracture pattern. Both emergency room physicians and

Mechanisms of Trauma	Predictable pattern of injuries
<b>Frontal Automotive Collision</b>	Cervical spine fracture; Sternal and Hip fractures; Posterior hip dislocation and fracture; Knee fractures and dislocation (ligament knee injuries); Ankle fractures and sprain; Long bones fractures;
<b>Lateral Automotive Impact</b>	Cervical spine fracture; Pelvic fracture; Acetabulum fractures; Upper and lower limb fractures;
<b>Rear Lateral Automotive Impact</b>	Cervical spine injuries; Neck soft-tissue injuries;
<b>Ejection from Vehicle</b>	The pattern of injury can be unpredictable as it depends on how the occupant lands. High overall mortality rate when comparing to any other mechanism of injury;
<b>Auto vs. Pedestrian Collisions</b>	Pelvic fractures; Lower limb fractures;
<b>Rapid Vertical Deceleration (falls)</b>	Pelvic fractures; Lower limb fractures; Acetabulum fractures; Lumbar spine fractures;
<b>Penetrating Trauma by Firearms</b>	The pattern of injury can be unpredictable.

Table 1: Mechanisms of trauma and the predictable pattern of injuries that may result.

Type	Wound size	Contamination	Soft tissue injury	Bone injury
I	<1cm	Clean	Minimum	Simple
II	>1cm	Moderate	Moderate	Moderate
IIIA	<10cm	Extensive	Severe possible coverage	Comminuted fracture
IIIB	>10cm	Extensive	Severe, impossible coverage	Comminuted fracture
IIIC	>10cm	Extensive	Vascular injury requiring repair	Comminuted fracture

Table 2: Open fracture classification (Gustilo & Anderson).

orthopedists should be familiar with this devised schema which dictates surgical intervention and antibiotic coverage. In an effort to streamline care in the ER, certain objectives and assessments should be met.

**OBJECTIVES**

- Identification of extremity trauma that leads to life-threatening conditions, disability, or limb loss;
- Standardization of care and treatment of trauma patients with extremity injury;
- Requisition of proper radiography according to the affected limb segment;
- Knowledge of the principles and methods of fracture stabilization;

lization;

- Identification of any trauma to an extremity that needs immediate surgical intervention;

**PRIMARY ASSESSMENT**

There are two groups of patients with extremity trauma that physicians will evaluate in emergency situations:

**Group 1:** Multiple-trauma patients that demonstrate a high level of consciousness and orientation;

**Group 2:** Unconscious and disoriented patients with multiple trauma injuries. Etiologies may include Traumatic Brain Injury (TBI), hypovolemic shock, hypoxia, drug intake, immaturity

(children) or by senile dementia (elderly).

Easily identifying a patient's group may help emergency physicians to deliver safer care and prevent iatrogenic injuries. The assistance to trauma victim begins with obtaining a concise history of the accident, which may be provided by the patient themselves or by others and by evaluating the mechanism of trauma – provided by pre-hospital care team (Table 1).<sup>1-3</sup> Regarding patients in Group 1, it is essential to obtain vital information about the accident and the body region injured, which the patient will identify as painful and/or with a functional disability. Patients in Group 2 must be fully unclothed and carefully inspected. Bruises, abrasions, bleeding, and deformities must be identified, providing evidences on possible trauma mechanism. Hypothermia must likewise be assessed and prevented.

During Circulatory assessment (C), after airway maintenance, cervical spine protection, (A) and ventilation (B), it is mandatory to recognize and control hemorrhage from musculoskeletal injuries. Deep lacerations may affect large vessels, causing profuse bleeding and subsequent hypovolemic shock. Direct pressure is the best way to control the bleeding. In 28% to 47% of cases, pelvic fractures are responsible for the cause of shock, requiring early stabilization for adequate control of bleeding.<sup>4-12</sup> Approximately 3% of patients present with a life-threatening hemorrhage due to isolated pelvic injury.<sup>6,10,13</sup> Consequently, the pelvic bleeding must be detected and distinguished from abdominal bleeding within the first few minutes after presentation. Long bone fractures, humerus, femur, and/or tibia, even when not open may provoke massive bleeding and subsequent hypovolemic shock i.e. Grade III (30-40% loss of blood volume). Ultimately, these injuries could result in a compartment syndrome with significant sequelae. In these cases, the correct fracture immobilization can significantly reduce bleeding and provide pain relief. The procedure should be performed during the resuscitation period, often without appropriate radiographic evaluation, due to the risk of imminent death. An important complement to bleeding control measures is intravenous fluid resuscitation including crystalloids and blood products.<sup>14,15</sup>

## SECONDARY ASSESSMENT

Once the patient has a patent airway, adequate breathing and cardiovascular stability, a full assessment of the musculoskeletal system (based on the information obtained, physical examination and imaging studies) must be done. The secondary survey should consist of acquiring more information about the patient's past medical history (allergies, past illnesses/pregnancies, last meal, events or environmental conditions related to injury). Along with the repeat head-to-toe physical examination, there must be a reassessment of vitals and ABC's.

## PHYSICAL EXAMINATION

The first step on physical examination is to make sure

the patient is fully unclothed, but to prevent hypothermia. Where relevant, the immobilization devices used at the crash scene are provisionally withdrawn (except the femoral traction device, when applicable) and put back after the examination when appropriate. The use of radio-transparent splints are recommended.<sup>16</sup> The bandages are removed, the wounds are inspected and new bandages are applied with sterile equipment.<sup>17</sup>

### Pertinent to patients of group 1 (conscious and oriented)

**A) Inspection:** Examine from head to toe, searching for swelling, abrasions, injuries, hyperemia, and deformities that may suggest a fracture or dislocation. Make a comparative examination with the other limb when possible.

**B) Active Motions:** Should be done only if the patient is able to do so. Even when the movements are preserved, joint damage should not be ruled out. Ask the patient to raise their arms, flex and extend the elbows, wrists and fingers. Ask the patient to flex and extend their hips, knees, ankles, and feet. Comparison should be made with contralateral limb. In cases of asymmetry or when the patient cannot perform the movements, carry out palpation, passive motion and always check the pulses.

**C) Palpation:** This should be performed carefully. Initially palpate suspicious lesion areas, searching for tender points, bony protrusions and crackles. Palpation may be performed in conjunction with passive mobilization.

**D) Passive motion:** Helps identify occult fractures and joint injuries. Check if there is pain and evaluate stamina and endurance during the movement.

**Emergency Room Radiography Request:** Cervical (Lateral), Chest (AP), Pelvis (AP) plus affected and suspected musculoskeletal segments.<sup>18</sup>

### Pertinent to patients of Group 2 (unconscious and disoriented)

**A) Inspection:** Observe from head to toe, looking for swelling, abrasions, injuries, hyperemia, and deformities that may suggest a fracture or dislocation. Make comparative examination of the contralateral extremity.

**B) Palpation:** In this group, palpation should be performed in a systematic way to ensure that no segment is missed. The suggestion is that a top-down palpation should be done in the following order: clavicle, shoulders, arms (humerus), elbow (epicondyles, olecranon and radial head), forearm (radius and ulna), wrists (radial styloid, ulnar and carpal), hands (metacarpal, metacarpophalangeal joints, phalanges, and interphalangeal joints), hip (iliac crests, pubis, ischial tuberosity, greater trochanter), thighs (lateral side of the femur), knee (patella, epicondyles, fibular head).

Observe joint effusion, leg (tibia and fibula crest), ankles (lateral and medial malleolus) and foot (calcaneus, tarsal, metatarsal, metatarsal-phalangeal joints, and phalanges). Always perform comparative palpation. Palpate peripheral pulses and test the deep tendon reflexes.

**C) Passive motion:** Helps identify occult fractures and joint injuries. If there is visible damage/ deformity, passive movement becomes unnecessary.

**Emergency Room Radiography Request:** Total Column (L + AP), Thorax (AP), pelvis (AP) segments showing signs of bruising, abrasions, bleeding and apparent deformities.

## COMPLIMENTARY IMAGE ASSESMENT

### Radiography

Table 3 represents the most common segments and incidences encountered in the emergency room.

### Important Notes:

- Radiographs should and can be taken with radio-transparent immobilization devices;
- Radiographs must contain the adjacent joints of the affected segment;

SEGMENT	X –RAY INCIDENCES	PROBABLE DIAGNOSIS
Clavicle	AP Axial 30° cephalad	Fracture: proximal, middle and distal; dislocation of the sternoclavicular or acromioclavicular joint.
Shoulder	AP + L Y-Scapular View Axillary View	Fracture of neck, anatomical, greater or lesser tuberosities and associated anterior or posterior dislocations.
Arm	AP + L (+ shoulder and elbow)	Humeral fracture of the upper, middle or lower 1/3; diaphyseal simple or complex.
Elbow	AP + L	Fracture of intra or extra-articular condyles; humeral-ulnar dislocation, dislocation of the radial head, fracture of the ulna with dislocation of the radial head, fracture of the radial head
Forearm	AP + L (+ elbow and wrist)	Proximal, middle or distal 1/3 radial diaphysis fracture and / or ulna; associated dislocation of the proximal or distal radio-ulnar joint
Wrist	AP + L (+ elbow)	Fracture of the distal 1/3 of the radius and / or ulna; fracture and / or dislocation of the carpal bones.
Hand	AP + Oblique	Fracture of the metacarpals and phalanges; dislocation of the metacarpophalangeal and interphalangeal.
Pelvis	AP + " in let" + "out let" (+ Lumbar spine femurs and knee)	Fractures of the ilium, ischium and pubis without amendment of the pelvic ring; fractures with alteration of the pelvic ring: lock (lateral compression); opening (anteroposterior compression) or vertical shear, fracture or dislocation of the acetabulum; fractures the proximal femur, anterior dislocation, central or posterior hip
Thigh	AP + L (Pelvis and knees)	Fractures of the proximal, middle or distal 1/3 femoral shaft.
Knee	AP + L + Oblique Patella (axial)	Fractures of intra-or extra-articular femoral condyles, tibial plateau fractures, fractures of the patella, femur-tibia or femur-patellar dislocations
Leg	AP + L (+ knee and ankle)	Fracture of the proximal, middle or distal 1/3, diaphysis of the tibia and / or fibula.
Ankle	AP + L	Fracture of the tibia, fracture of the lateral, medial malleolus or both. With or without dislocation of the tibio-tarsal joint
Foot	AP + O + (L) (+ ankle)	Fracture of the calcaneus, talus, tarsal bones, metatarsals and phalanges; dislocation articular calcanealtarsal (Chopart), tarsal-metatarsal (Lisfranc) or interphalangeal

**Table 3:** Radiography by segment and incidences followed by probable diagnosis found in each complimentary exam.

- Do not accept poor quality radiographs;
- In case of children and adolescent with joint trauma, the radiograph of the contralateral limb is mandatory. Otherwise, the cartilaginous structures and epiphyseal growth plates can be misdiagnosed as a fracture.

## IMMOBILIZATION

**Note:** All procedures should be done after the removal of all structures that may cause constriction such as: bandages, jewelry, rings, watches, etc., and the patient should always be placed on the long spine board for transportation. Once in the emergency room, the backboard can be removed when spinal injuries are cleared.<sup>19,20</sup>

### Principles of Immobilization

Where relevant, immobilization should be performed at the crash scene before the patient is transported to the hospital. The use of slings, splints, traction, cervical collar, and long spine board is important for the correct treatment of multiple trauma patients. The basic principle of fracture management is always to immobilize the joint above and below the injured bone. Extremities trauma care should be carried out in the secondary assessment, after the treatment of injuries that endanger the patient's life.

#### A) Upper Extremity

- **Hand and wrist:** These injuries should be immobilized in the anatomical position, with a volar splint for the wrist or volar splint for fingers, discrete wrist dorsiflexion, slight flexion of the fingers, and a sling.
- **Forearm:** Immobilization should contain the elbow (90° flexion) and wrist (in neutral position): axillary-hand palm-splint.
- **Elbow:** Immobilize the elbow in a semi-flexed position (30-40°) with axillary-palmar splint. If there is any resistance to move the limb back to its anatomical position, immobilize in the position it was found with an axillary- hand palm-splint.
- **Arm:** Shoulder and elbow should be immobilized, usually by bandaging the arm close to the chest or temporary axillary-hand palmsplints.
- **Shoulder:** The immobilization should be done with the arm close to the chest using bandage or just a sling.
- **Clavicle:** Initial placement of an inter-scapular pad helps to relieve pain and can be maintain edif the patient remains bedridden. The use of a sling may help during transportation. Figure-of-eight bandage (clavicle strap) is employed for middle-third fractures as definitive treatment.<sup>19</sup>

#### B) Lower Extremity

- **Femur:** Can be carefully immobilized with a traction device applied on the ankle, avoiding application closer to major wounds. Immobilization can be done by bandaging one leg to the other. This type of immobilization is also used for hip fractures.
- **Tibia and fibula:** Should be held in place with a cruropodal rigid splint or pneumatic splint above the knee and below the ankle.
- **Knee:** Splinting with slight traction or discrete flexion, with a pad under the knee to reduce discomfort.
- **Ankle:** These injuries can be immobilized with pillows or padded splints with 90° of dosiflexion, avoiding pressure on the malleolus and bony prominences.
- **Feet:** Also immobilized with a leg-foot splints.<sup>20</sup>

## TRAUMAREQUIRINGIMMEDIATEOPERATIVE INTERVENTION

### Unstable Pelvis Fractures

Complex pelvic ring injuries are generally not isolated and are usually observed in patients with multiple trauma, therefore the patient requires critical care. Facing a polytraumapatient with severe fractures involving the pelvic ring, the physician should keep in mind the overall management of the patient including all associated traumatic injuries in addition to management of the pelvic fracture (s).

On physical examination, the emergency physician should look for possible ecchymotic areas, bruising or bleeding near the urethral meatus, vagina, or rectum. If these later two regions are not carefully inspected, an open pelvis fracture may be missed.

Pelvic instability can be simply tested by gently applying lateral and anteroposterior pressure with the thenar region of both hands on the iliac crests, and by holding the hemipelvis with one hand and using the other hand to pull along the vertical plane.<sup>6, 21,22</sup>

### Emergency care

#### Protocol for shock in pelvic fracture

Initial assessment (A,B,C) + IV fluid with poor or transient response:

- If external bleeding → Control
- If internal bleeding, unknown origin → proceed with chest, abdomen and pelvis radiological examination in the ER and perform a Focused Assessment with Sonography for Trau-

ma (FAST) exam. If patient is hemodynamically unstable activate the massive transfusion protocol

- Insert the Resuscitative Endovascular Ballon Occlusion of the Aorta (REBOA) in Zone I (from the origin of the left subclavian artery to the celiac artery) if FAST (+), and in Zone III (from the lowest renal artery to the aortic bifurcation) if FAST (-).<sup>23,24</sup>
- If chest bleeding → Thoracotomy may be necessary
- If bleeding origin is in the abdomen or pelvis associated with low risk fracture → Laparotomy may be necessary
- If bleeding origin is in the abdomen or pelvis associated with a high risk pelvic fracture → proceed with pelvic packing and external fixation to stabilize the pelvic fracture and reduce the bleeding

Despite efforts, the mortality rate of unstable pelvic fractures has remained high. It seems that multidisciplinary care is not enough for reducing the mortality of this condition.<sup>23-25</sup> REBOA has emerged as an alternative to control bleeding and stabilizes patients in hemorrhagic shock. A revised algorithm for the management of patients with unstable pelvic fractures and exsanguinating hemorrhage is detailed in Figure 1.<sup>23</sup>

A particularly dangerous situation occurs if the patient is subjected to an emergency laparotomy hastily, wherein an unstable pelvic fracture may be an unknown bleeding source. It is important to stabilize the pelvis and fix an open-book injury with an external fixator before laparotomy is performed. Special attention must be given to “over-resuscitated” patients. Overload crystalloid resuscitation must be avoided and can cause a false positive FAST exam. For pelvic fractures with severe shock and no obvious bleeding source, extraperitoneal packing and/or REBOA before an angio-CT and external fixation are highly recommended. In the case of patient presenting with an acetabulum

fracture (not pelvic ring fracture) in severe shock, the ER physician should strongly suspect a vascular injury (iliac artery and/or vein).

**OPEN FRACTURES**

Open fracture occurs when there is communication between the fracture and the external environment or infected cavities such as mouth, digestive tract, vagina, and anus. The existence of an open wound around a fracture should be considered as an open fracture until proven otherwise. The presence of air in soft tissue in the radiological examination suggests exposure of the injury to the environment.<sup>26</sup>

**Initial Approach**

**At the scene of trauma:** The assistance to the patient with an open fracture should begin at the trauma scene. The wound should be isolated from contaminated external environment as soon as possible. At this time, it is ideal to apply gauze or sterile compresses. If not available, clean clothes or clean plastic sheets are acceptable. Improvised immobilization may help prevent further trauma to soft tissues, but an attempt to reducing the open fracture should be avoided due to the risks of bringing debris and microbial contaminants into the wound.

**At the hospital:** It is mandatory to isolate the wound, if not already done. If there is a need to examine the wound, it should be done quickly (minimal time) and in a favourable environment, preferably by the orthopedic surgeon who will treat the fracture. At this time, the emergency physician can classify the fracture exposure level (Table 3), which may help designate the antibiotic therapy (Table 4) and the method of stabilization. Do not forget to give the anti-tetanus immunization according to vaccination history.<sup>27-31</sup>

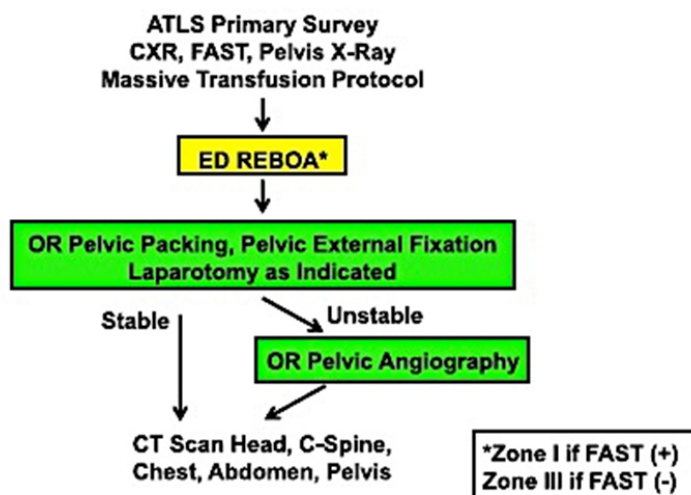


Figure 1: Management of Patient with Unstable Pelvic Fractures and Severe Hemorrhagic Shock (Revised Denver Health Medical Center Algorithm).<sup>23</sup>

Type	Antibiotic
I and II	Cephalosporin(1 <sup>st</sup> generation)
IIIA, B, C	Cephalosporin(1 <sup>st</sup> generation)+aminoglycosides
In countryside, field or farm	Cephalosporin(1 <sup>st</sup> generation)+aminoglycosides+ Penicillin

Table 4: Antibiotic therapy in open fractures (OF)\*.

### Antibiotic Therapy in Open Fractures

#### Important:

1. These fractures should be operated (extensive washing, debridement and stabilization) within 6 hours after trauma, otherwise they are considered infected.
2. These wounds should NOT be initially sutured, regardless of wound size and contamination, even when the patient needs to be transferred to another hospital.

### TRAUMATIC AMPUTATION

Traumatic amputation is the most catastrophic extremity injury, which endangers limb viability and patient life. Amputations should be promptly treated, with compression or tourniquet to stop the bleeding. The limb must be properly evaluated and preserved for possible implantation

There are two types of amputation: total, in which the limb is fully separated from the patient; and partial, in which the limb is connected by tissue with little or no vitality.<sup>32</sup>

#### Treatment:

- Partial Amputation: control bleeding; compression bandage or tourniquet – taking note of the time it was done. Do not clamp vessels; clean the injured extremity; bandages should be sterile; and immobilize.
- Total Amputation: The same as discussed in “Partial Amputation”. In particular, the limb must be packed in clean dry bandages and always together with the patient to ensure that both arrive at the same time in the hospital. The limb to be implanted should be in hospital at room temperature not greater than 6 hours after trauma, or preserved in a dry plastic bag put on ice-filled box not greater than 18 hours after the accident. Never place the severed limb directly on ice, water, dry ice or in the freezer.<sup>33,34</sup> In severe limb injuries, early fasciotomy may improve limb viability and avoid amputations.<sup>32,35</sup>

### FRACTURES ASSOCIATED WITH VASCULAR INJURY

The prognosis of fractures associated with vascular injury depends on the duration and degree of ischemia. The degree of tissue ischemia is aggravated in multiple trauma patients by

generalized hypoxia. Prompt diagnosis and direct treatment of vascular injury reduces further damage. The presence of pulse or a Doppler signal does not exclude vascular injury. The arterial injury reconstruction has priority over the bone fixation. If immediate repair is difficult to be executed, a temporary shunt is recommended.<sup>36-39</sup>

### FRACTURES WITH COMPARTMENT SYNDROME

Compartment syndrome can lead to subsequent muscular, nervous, and vascular damage. Appreciation of a developing compartment syndrome is extremely important and may contribute to efforts aimed at limb salvage. The classic symptoms, known as the “four Ps” of Griffiths, are: pain, paresthesia, paresis, and pulselessness. The pain may be the first and most important symptom of an impending compartment syndrome. In general, it is described as being much more severe than expected (pain out of proportion to what should be experienced from a physical examination), difficult to control with common analgesics, and the intensity is exacerbated with passive extension of muscle.<sup>40,41</sup>

Since the high pressure in the tissue is the prime condition for the establishment of compartment syndrome, direct measurement of this pressure is the most objective way to make the diagnosis. (Whitesides Method). The most recent evidence suggests that the limits of pressure and time are between (30-40) mm Hg and eight hours. With high pressures extending over eight hours, intracompartmental necrosis will occur. Hence, an immediate fasciotomy should be performed. It is necessary to know the anatomy of the compartments of each limb before fasciotomy, avoiding inadequate fasciotomy which, in and of itself, will result in subsequent tissue necrosis.<sup>42-44</sup>

In multiple trauma patients, irreversible tissue damage may occur at a lower compartment pressure due to generalized hypoxia. High-risk patients, especially those with closed comminuted fractures of the proximal or distal-third tibia or those with complex foot injuries, should be closely monitored. It is important to emphasize that not only fractures can induce compartment syndrome, but contusions involving high-energy trauma and extrinsic factors such as tight bandage or splinting are also related to increase compartment pressure. Delayed presentation of compartment syndrome is uncommon.<sup>45</sup> Attention must be given to fractures near the elbow in children. These fractures (supracondylar) should not be immobilized with circular plaster and flexion greater than 90 degrees due to risk of complications. Contusion or crushing should be observed in the acute phase and an anti-inflammatory therapy should be performed, otherwise it can progress to compartment syndrome.

### ASSOCIATED VASCULAR, TENDON AND NERVE INJURIES

Hemorrhage endangers life and must be quickly and effectively controlled. The correct way is applying an occlusive



bandage with sterile dry gauze. Another option is to stop the bleeding, and placement of vascular clamps and/or tourniquets should be avoided as these procedures may cause more damage to the vessels and the surrounding structures. After hemorrhage control and optimal fluid resuscitation, the treatment of the wound should be initiated. The principles of wound care consist of preventing infection, promoting primary healing, and saving the injured tissues. The ER physician should, through history and physical examination, evaluate what procedures must be urgently performed. The history should contain data about the time between the accident and treatment, contamination of the lesion, the mechanism of trauma, and the procedures performed. Physical examination should be done under sterile conditions in order to calculate the size of the wound, the extent of tissue loss, and viability of the surrounding tissues. Distal limb perfusion must be evaluated in case of suspected arterial lesion associated with a perfusion deficit. Salvage of the limb in a critical trauma patient may be difficult especially in the presence of physiologic derangements (i.e. coagulopathy, hypothermia, and acidosis); however, successful cases have been reported. The vascular exploration should be done in an operating room by a surgeon competent in vascular surgery.<sup>46-48</sup>

The diagnosis of a tendon injury can be done at the first examination by an abnormal digital posture. In patients who can cooperate, separate tests to evaluate the damage of superficial and deep flexor tendons or both can be performed. Before the anesthetic block, the diagnosis of nerve injury is done by performing a sensory examination in the anatomic areas (dermatomes) supplied by the median, radial, and ulnar nerves.

**Initial treatment:** After quick inspection of the wound and the limb, take the following steps:

- Start a broad-spectrum antibiotic (cephalothin 2g IV or 25 mg/kg);
- Administer an anti-tetanus immunization, according to prior vaccination history;
- Avoid locally anesthetizing the wound if there is possibility of transferring the patient to a orthopedic surgeon.
- If not, block the edges of the wound with Lidocaine 1% and wash the wound with normal saline (at least 1 liter);
- Approximate the wound edges with non-absorbable sutures;
- Occlusive bandage with sterile gauze should be performed to stop the bleeding;
- Maintain temporary immobilization;
- DO NOT tie or clamp bleeding vessels, just apply an occlusive bandage;
- DO NOT suture the fascia, muscles, tendons, or nerves;
- Transfer to the hospital with optimal facility and for an orthopedist evaluation.

## OTHER IMPORTANT SITUATIONS

**1. Traumatic dislocation of the shoulder (glenohumeral joint):** Characterized by acute shoulder dislocation, with severe pain, apparent deformity and functional disability. In anterior dislocations, the arm is abducted and externally rotated, with limitation of internal rotation. In the posterior dislocations (rarer), the shoulder external rotation is limited and the arm is abducted and internally rotated. It should be noted an anterior dislocation occurs in 85-90% of cases and that the axillary nerve is at risk.

### Treatment

- Request radiographs AP + Lateral (L) + Axillary of the affected shoulder. Note: If in doubt, compare with the unaffected shoulder; Y-scapular view may be required to identify posterior displacement.
- Put the patient lying on a stretcher;
- Do effective analgesia (i.e.: opioids) and muscle relaxing (Diazepam);
- Make the traction and counter-traction maneuvers;
- Reduction occurs when there is immediate pain relief and return to normal shape of the shoulder;
- Immobilize
- If not reduce, put a sling and refer the patient to an orthopedic surgeon.

**2. Dislocations (in general):** Dislocations should not be underestimated. The energy required to promote the displacement of a joint, often, is greater than that required to fracture a bone. Thus, it should be faced as an emergency and treated promptly, preferably in the operating room under anesthesia. The reduction of a dislocation gives immediate discomfort and pain relief. Whenever possible, reduction maneuvers must be performed by an orthopedist. These maneuvers should not exceed more than two attempts, because in that case the treatment is surgical, and insisting on maneuvers may worsen the injury. Always assess and document the distal pulses before and after reduction.

**3. Fracture of the femoral neck:** These fractures, especially in young people, endanger the vascularity of the femoral head and may lead to aseptic necrosis of the femoral head with severe sequelae and disability to the patient. When treated early (within 8 hours post-trauma), the occurrence of necrosis decreases.

If this injury is suspected, AP radiographs of pelvis with 15-20 degrees internal rotation of the lower limbs and L of the affected hip should be requested. The treatment of these fractures is surgical and preference given to techniques of osteosynthesis. In elderly patients, these fractures should also be treated early to prevent necrosis of the femoral head and especially morbidities from the confinement to bed (e.g., pneumonia, urinary

tract infections, pressure sores, venous thromboembolism, and death).

**4. Diaphyseal femur fracture:** This fracture is caused by high-energy mechanisms, usually with extensive soft tissue injury, associated injuries and blood loss (even in closed fractures). The provisional immobilization relieves pain, prevents further damage to the soft tissue, reduces bleeding and can decrease the risk of fat embolism syndrome. Increasingly, there is a trend to operate early in these fractures because of associated complications. Intramedullary rodding is currently the treatment of choice in diaphyseal fractures with application of superior and distal locking screws to prevent rotational or shortening deformities.

**5. Closed fractures (in general):** All diagnosed fractures should be treated, even by a simple immobilization. Thus, all fractures should be considered an emergency.

**FINAL CONSIDERATIONS**

An attempt has been made to highlight the main extremity injuries which endanger patient’s life or the result in loss of the affected limb, commonly seen in emergency departments worldwide. The presented protocols are based on updated literature and accepted in most services. Emergency physicians

should consider this content when managing fractures and/or dislocations, paying special attention to those that need emergency treatment. In all cases, after the initial procedure, the patient should be referred for an orthopedic evaluation. An emergency room extremity trauma management flowchart is presented (Figure 2).

**CONSENT**

No consent is required to this article publication.

**CONFLICTS OF INTEREST**

The authors declare that there are no conflicts of interest.

**REFERENCES**

1. Brown JB, Stassen NA, Bankey PE, Sangosanya AT, Cheng JD, Gestring ML. Mechanism of injury and special consideration criteria still matter: an evaluation of the National Trauma Triage Protocol. *The Journal of trauma*. 2011; 70(1): 38-44. doi: 10.1097/TA.0b013e3182077ea8
2. Beuran M, Negoï I, Paun S, Runcanu A, Gaspar B. Mechanism of injury-trauma kinetics. What happens? How?. *Chirurg-*

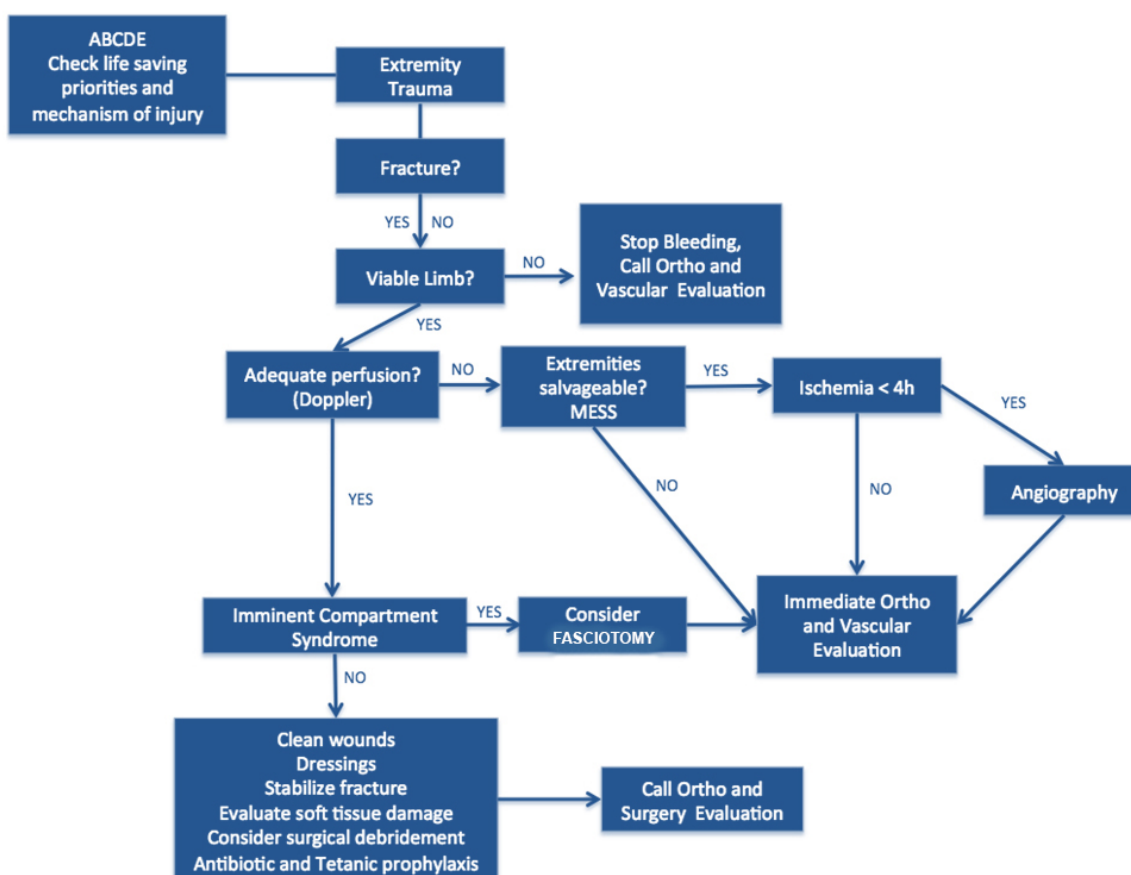


Figure 2: Extremity Trauma algorithm for emergency physicians.

ia (Bucur). 2012; 107(1): 7-14.

3. Gross E, Martel M. Multiple Trauma, Rosen's Emergency Medicine. 7<sup>th</sup> ed. 2010.

4. Hougaard K, Vester AE, Holme JB, Nielsen DT, Christensen EF. Initial treatment of patients with unstable pelvic fractures and hemorrhagic shock. *Ugeskrift for laeger*. 2003; 165(45): 4291-4294.

5. Tanizaki S, Maeda S, Matano H, Sera M, Nagai H, Ishida H. Time to pelvic embolization for hemodynamically unstable pelvic fractures may affect the survival for delays up to 60min. *Injury*. 2014; 45(4): 738-741. doi: [10.1016/j.injury.2013.11.007](https://doi.org/10.1016/j.injury.2013.11.007)

6. Tonetti J. Management of recent unstable fractures of the pelvic ring. An update conference supported by the Club Bassin Cotyle. (Pelvis-Acetabulum Club). *Orthopaedics & traumatology, surgery & research: OTSR*. 2013; 99(1 Suppl): S77-S86. doi: [10.1016/j.otsr.2012.11.013](https://doi.org/10.1016/j.otsr.2012.11.013)

7. Sen RK, Gopinathan NR, Tamuk T, Kumar R, Krishnan V, Sament R. Predictors of early outcome in unstable pelvic fractures. *Chinese journal of traumatology=Zhonghua chuang shang za zhi/Chinese Medical Association*. 2013; 16(2): 94-98.

8. Linan-Padilla A, Giraldez-Sanchez MA, Serrano-Toledano D, Lazaro-Gonzalvez A, Cano-Luis P. Patients with hemodynamic unstable pelvic fractures in extremis: pelvic packing or angiography? *Spanish Journal of Chirurgia Ortopedica*. 2013; 57(6): 429-433. doi: [10.1016/j.recot.2013.07.002](https://doi.org/10.1016/j.recot.2013.07.002)

9. Thorson CM, Ryan ML, Otero CA, et al. Operating room or angiography suite for hemodynamically unstable pelvic fractures? *The journal of trauma and acute care surgery*. 2012; 72(2): 364-370. doi: [10.1097/TA.0b013e318243da10](https://doi.org/10.1097/TA.0b013e318243da10)

10. Gansslen A, Hildebrand F, Pohlemann T. Management of hemodynamic unstable patients "in extremis" with pelvic ring fractures. *Acta chirurgiae orthopaedicae et traumatologiae Cechoslovaca*. 2012; 79(3): 193-202.

11. Burlew CC, Moore EE, Smith WR, et al. Preperitoneal pelvic packing/external fixation with secondary angioembolization: optimal care for life-threatening hemorrhage from unstable pelvic fractures. *Journal of the American College of Surgeons*. 2011 Apr; 212(4): 628-635. doi: [10.1016/j.jamcollsurg.2010.12.020](https://doi.org/10.1016/j.jamcollsurg.2010.12.020)

12. Banerjee M, Bouillon B, Shafizadeh S, Paffrath T, Lefering R, Wafaisade A. Epidemiology of extremity injuries in multiple trauma patients. *Injury*. 2013; 44(8): 1015-1021. doi: [10.1016/j.injury.2012.12.007](https://doi.org/10.1016/j.injury.2012.12.007)

13. White CE, Hsu JR, Holcomb JB. Haemodynamically unstable pelvic fractures. *Injury*. 2009; 40(10): 1023-1030.

14. Clark JD. Femur fractures: complications & treatments of traumatic femoral shaft fractures. *JEMS: a journal of emergency medical services*. 2003; 28(4): 68-81.

15. Steffner RJ, Lee MA. Emerging concepts in upper extremity trauma: humeral shaft fractures. *The Orthopedic clinics of North America*. 2013; 44(1): 21-33. doi: [10.1016/j.ocl.2012.08.005](https://doi.org/10.1016/j.ocl.2012.08.005)

16. Schuind F, Moulart F, Liegeois JM, Dejaie L, Strens C, Burny F. Orthopedic immobilization. *Acta orthopaedica Belgica*. 2002; 68(5): 439-461.

17. Eardley WG, Watts SA, Clasper JC. Extremity trauma, dressings, and wound infection: should every acute limb wound have a silver lining? *The international journal of lower extremity wounds*. 2012; 11(3): 201-212. doi: [10.1177/1534734612457028](https://doi.org/10.1177/1534734612457028)

18. Driscoll P, Skinner D. ABC of major trauma. Initial assessment and management--I: Primary survey. *BMJ*. 1990; 300(6734): 1265-1267. doi: [10.1136/bmj.300.6734.1265](https://doi.org/10.1136/bmj.300.6734.1265)

19. Wolf JM, Athwal GS, Shin AY, Dennison DG. Acute trauma to the upper extremity: what to do and when to do it. *The Journal of bone and joint surgery American volume*. 2009; 91(5): 1240-1252.

20. Tintle SM, Keeling JJ, Shawen SB, Forsberg JA, Potter BK. Traumatic and trauma-related amputations: part I: general principles and lower-extremity amputations. *The Journal of bone and joint surgery American volume*. 2010; 92(17): 2852-2868. doi: [10.2106/JBJS.J.00257](https://doi.org/10.2106/JBJS.J.00257)

21. Hasankhani EG, Omid-Kashani F. Treatment outcomes of open pelvic fractures associated with extensive perineal injuries. *Clinics in orthopedic surgery*. 2013; 5(4): 263-268.

22. Black EA, Lawson CM, Smith S, Daley BJ. Open pelvic fractures: the University of Tennessee Medical Center at Knoxville experience over ten years. *The Iowa orthopaedic journal*. 2011; 31: 193-198.

23. Biffi WL, Fox CJ, Moore EE. The role of REBOA in the control of exsanguinating torso hemorrhage. *The journal of trauma and acute care surgery*. 2015; 78(5): 1054-1058. doi: [10.1097/TA.0000000000000609](https://doi.org/10.1097/TA.0000000000000609)

24. Martinelli T, Thony F, Decléty P, et al. Intra-aortic balloon occlusion to salvage patients with life-threatening hemorrhagic shocks from pelvic fractures. *The Journal of trauma*. 2010; 68(4): 942-948. doi: [10.1097/TA.0b013e3181c40579](https://doi.org/10.1097/TA.0b013e3181c40579)

25. Biffi WL, Smith WR, Moore EE, et al. Evolution of a multidisciplinary clinical pathway for the management of unstable patients with pelvic fractures. *Annals of surgery*. 2001; 233(6): 843-850.

26. Scalea TM, DuBose J, Moore EE, et al. Western Trauma Association critical decisions in trauma: management of the mangled extremity. *The journal of trauma and acute care surgery*. 2012; 72(1): 86-93. doi: [10.1097/TA.0b013e318241ed70](https://doi.org/10.1097/TA.0b013e318241ed70)
27. Barton CA, McMillian WD, Crookes BA, Osler T, Bartlett CS, 3rd. Compliance with the Eastern Association for the Surgery of Trauma guidelines for prophylactic antibiotics after open extremity fracture. *International journal of critical illness and injury science*. 2012; 2(2): 57-62. doi: [10.4103/2229-5151.97268](https://doi.org/10.4103/2229-5151.97268)
28. Gustilo RB, Anderson JT. Prevention of infection in the treatment of one thousand and twenty-five open fractures of long bones: retrospective and prospective analyses. *J Bone Joint Surg [Am]*. 1976; 58-A: 453-458.
29. Papakostidis C, Kanakaris NK, Pretel J, Faour O, Morell DJ, Giannoudis PV. Prevalence of complications of open tibial shaft fractures stratified as per the Gustilo-Anderson classification. *Injury*. 2011; 42(12): 1408-1415. doi: [10.1016/j.injury.2011.10.015](https://doi.org/10.1016/j.injury.2011.10.015)
30. Horn BD, Rettig ME. Interobserver reliability in the Gustilo and Anderson classification of open fractures. *Journal of orthopaedic trauma*. 1993; 7(4): 357-360.
31. Hospenthal DR, Murray CK, Andersen RC, et al. Guidelines for the prevention of infections associated with combat-related injuries: 2011 update: endorsed by the Infectious Diseases Society of America and the Surgical Infection Society. *The Journal of trauma*. 2011; 71(2 Suppl 2): S210-S234. doi: [10.1097/TA.0b013e318227ac4b](https://doi.org/10.1097/TA.0b013e318227ac4b)
32. Doukas WC, Hayda RA, Frisch HM, et al. The Military Extremity Trauma Amputation/Limb Salvage (METALS) study: outcomes of amputation versus limb salvage following major lower-extremity trauma. *The Journal of bone and joint surgery American volume*. 2013; 95(2): 138-145. doi: [10.2106/JBJS.K.00734](https://doi.org/10.2106/JBJS.K.00734)
33. Jacobs C, Siozos P, Raible C, et al. Amputation of a lower extremity after severe trauma. *Operative Orthopadie und Traumatologie*. 2011; 23(4): 306-317. doi: [10.1007/s00064-011-0043-9](https://doi.org/10.1007/s00064-011-0043-9)
34. Tintle SM, Baechler MF, Nanos GP, 3rd, Forsberg JA, Potter BK. Traumatic and trauma-related amputations: Part II: Upper extremity and future directions. *The Journal of bone and joint surgery American volume*. 2010; 92(18): 2934-2945. doi: [10.2106/JBJS.J.00258](https://doi.org/10.2106/JBJS.J.00258)
35. Kragh JF, Jr., Wade CE, Baer DG, et al. Fasciotomy rates in operations enduring freedom and iraqi freedom: association with injury severity and tourniquet use. *Journal of orthopaedic trauma*. 2011; 25(3): 134-139. doi: [10.1097/BOT.0b013e3181e52333](https://doi.org/10.1097/BOT.0b013e3181e52333)
36. Fox N, Rajani RR, Bokhari F, Chiu WC, et al. Evaluation and management of penetrating lower extremity arterial trauma: an Eastern Association for the Surgery of Trauma practice management guideline. *The journal of trauma and acute care surgery*. 2012; 73(5 Suppl 4): S315-S320. doi: [10.1097/TA.0b013e31827018e4](https://doi.org/10.1097/TA.0b013e31827018e4)
37. Halvorson JJ, Anz A, Langfitt M, et al. Vascular injury associated with extremity trauma: initial diagnosis and management. *The Journal of the American Academy of Orthopaedic Surgeons*. 2011; 19(8): 495-504.
38. Kauvar DS, Sarfati MR, Kraiss LW. National trauma data-bank analysis of mortality and limb loss in isolated lower extremity vascular trauma. *Journal of vascular surgery*. 2011; 53(6): 1598-1603. doi: [10.1016/j.jvs.2011.01.056](https://doi.org/10.1016/j.jvs.2011.01.056)
39. de Oliveira Goes Junior AM, Vieira Abib SD, de Seixas Alves MT, da Silva Ferreira PS, de Andrade MC. To Shunt or not to Shunt ? An Experimental Study Comparing Temporary Vascular Shunts and Venous Ligation as Damage Control Techniques for Vascular Trauma. *Annals of vascular surgery*. 2013.
40. Schmidt AH. The impact of compartment syndrome on hospital length of stay and charges among adult patients admitted with a fracture of the tibia. *Journal of orthopaedic trauma*. 2011; 25(6): 355-357. doi: [10.1097/BOT.0b013e3181f18ad8](https://doi.org/10.1097/BOT.0b013e3181f18ad8)
41. Hope MJ, McQueen MM. Acute compartment syndrome in the absence of fracture. *Journal of orthopaedic trauma*. 2004; 18(4): 220-224.
42. Seigerman DA, Choi D, Donegan DJ, Yoon RS, Liporace FA. Upper extremity compartment syndrome after minor trauma: an imperative for increased vigilance for a rare, but limb-threatening complication. *Patient safety in surgery*. 2013; 7(1): 5.
43. Javadikasgari H. Incidence and predictors for the need for fasciotomy after extremity trauma. *Injury*. 2012; 43(7): 1226.
44. Farber A, Tan TW, Hamburg NM, et al. Early fasciotomy in patients with extremity vascular injury is associated with decreased risk of adverse limb outcomes: a review of the National Trauma Data Bank. *Injury*. 2012; 43(9): 1486-1491. doi: [10.1016/j.injury.2011.06.006](https://doi.org/10.1016/j.injury.2011.06.006)
45. Gaines RJ, Randall CJ, Browne KL, Carr DR, Enad JG. Delayed presentation of compartment syndrome of the proximal lower extremity after low-energy trauma in patients taking warfarin. *Am J Orthop (Belle Mead NJ)*. 2008; 37(12): E201-E204.
46. Park JJ, Campbell KA, Mercuri JJ, Tejwani NC. Updates in the management of orthopedic soft-tissue injuries associated with lower extremity trauma. *Am J Orthop (Belle Mead NJ)*. 2012; 41(2): E27-E35.

47. Fox CJ, Perkins JG, Kragh JF Jr, Singh NN, Patel B, Ficke JR. Popliteal artery repair in massively transfused military trauma casualties: a pursuit to save life and limb. *The Journal of trauma*. 2010; 69(Suppl 1): S123-S134. doi: [10.1097/TA.0b013e3181e44e6d](https://doi.org/10.1097/TA.0b013e3181e44e6d)

48. Prichayudh S, Verananvattna A, Sriussadaporn S, et al. Management of upper extremity vascular injury: outcome related to the Mangled Extremity Severity Score. *World journal of surgery*. 2009; 33(4): 857-863. doi: [10.1007/s00268-008-9902-4](https://doi.org/10.1007/s00268-008-9902-4)